




Changes in Subretinal Hyperreflective Material in Phase I/II Study of Proton Beam Irradiation combined with anti-VEGF Therapy for Exudative Age-Related Macular Degeneration



Jonathan Lu¹, Inder Daftari², Kavita Mishra², Ala Moshiri¹, Susanna S Park¹

Department of Ophthalmology & Vision Science, University of California Davis, Sacramento, CA.
Department of Radiation Oncology, University of California San Francisco, CA

Abstract:

Purpose: Since size of the subretinal hyperreflective material (SRHM) on OCT imaging has been correlated with long-term visual outcome in exudative age-related macular degeneration (eAMD) treated with intravitreal anti-vascular endothelial growth factor (VEGF), we tested the hypothesis that low dose proton beam treatment (PBT) with anti-VEGF reduced the volume of SRHM by reducing the fibrotic part in the choroidal neovascular membrane associated with eAMD.

Methods: Baseline 1 and 2 year OCT images of eyes completing 24 months of a prospective phase I/II randomized, prospective, sham-controlled study of PBT combined with antiVEGF therapy were analyzed for SRHM volume using the automated volume measure of subRPE lesion (Cirrus). Eyes were randomized 1:1:1 to 24GyE PBT, 16GyE PBT or sham radiation and followed for antiVEGF treatment as needed based on new OCT fluid and/or macular hemorrhage after three monthly antiVEGF.

Results: Among 30 eyes, interim analysis showed 15 completed 24 months of the study, and had OCT images. All showed SRHM, ranging 0.01-2.05 millimeters cubed (mm³) at baseline (mean 0.48 mm³ ± 0.62 mm³), 0-2.76 mm³ at 12 months (mean 0.38 mm³ ± 0.77 mm³), and 0.01-3.84 mm³ at 24 months (mean 0.51 mm³ ± 1.04 mm³). No significant difference in mean volume was noted among groups at 12 and 24 months. As measure of very small volume SRHM (i.e. < 0.01 mm³) has limited accuracy, further analysis was on 14 eyes with SRHM volume of > 0.01 mm³ at baseline (n=5 24GyE, n=3 16GyE, n=6 sham). The proportion with SRHM volume decreases by > 50% from baseline at 12 months was 3/5 in 24GyE, 3/3 in 16GyE, and 1/6 in sham, with a significant difference between PBT versus sham at 12 months (p = 0.03 by X²) and a trend at 24 months (p = 0.057 by X², 2/5 in 24GyE, 2/3 in 16GyE, and 0/5 in sham due to 1 eye not having 24-month imaging). Eyes with > 50% decrease in SRHM at 24 months had similar reduction in SRHM at 12 months.

Conclusions: Interim OCT analysis of eyes in this small prospective phase I/II sham controlled study of eAMD show a significantly higher proportion of eyes with greater than halving in volume of SRHM among eyes with eAMD treated with PBT and antiVEGF therapy as compared to antiVEGF monotherapy. This supports the hypothesis that low dose radiation with intravitreal antiVEGF may reduce the size of SRHM in eAMD. A larger study may be warranted to further characterize this effect.

Purpose:

While there have been improvements in the treatment of exudative age-related macular degeneration (eAMD), such as anti-vascular endothelial growth factor (VEGF) therapy, there has been interest in using proton beam radiation as adjuvant therapy to target the underlying fibrovascular proliferation,

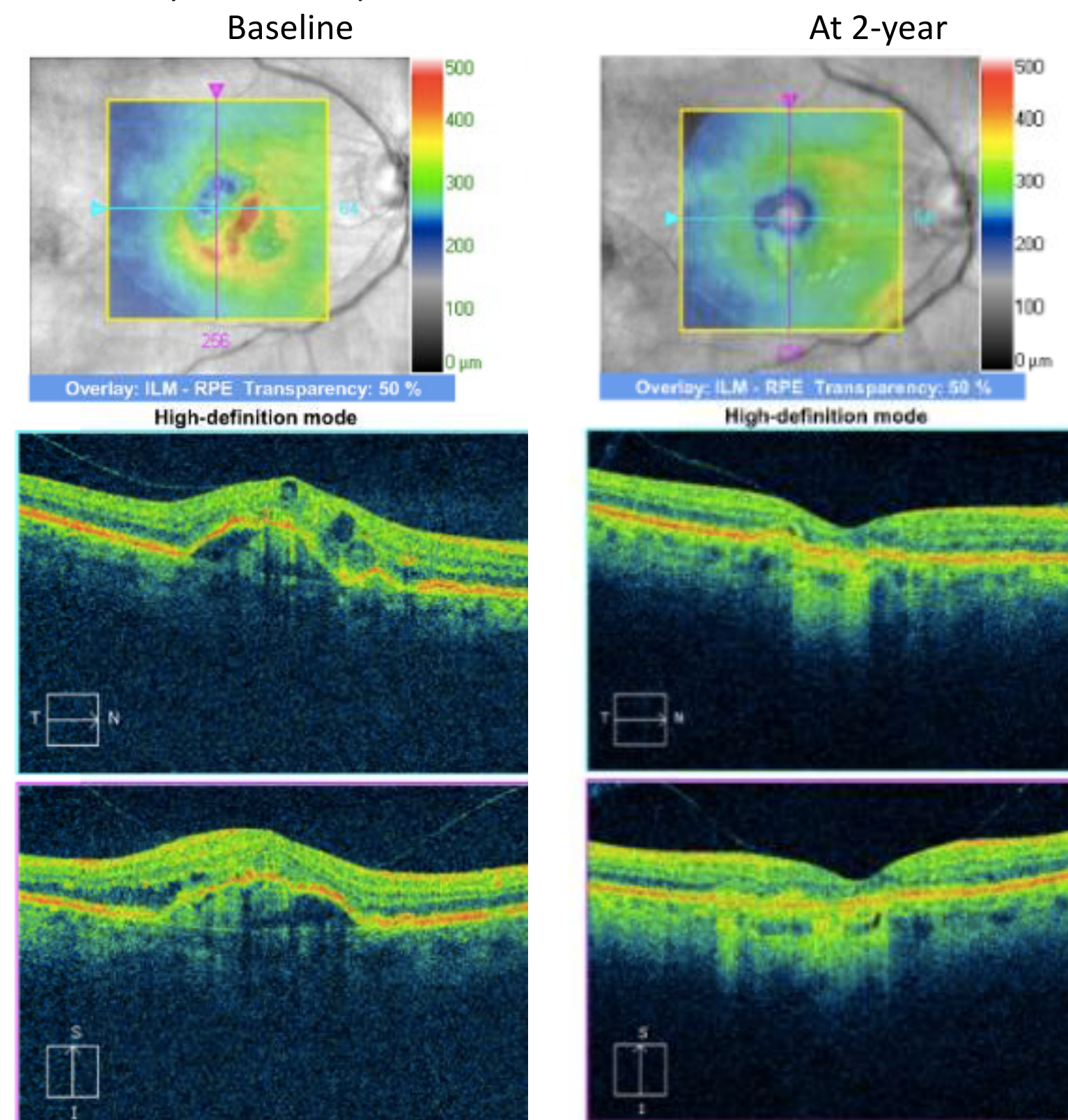
Since size of the subretinal hyperreflective material (SRHM) on OCT imaging has been correlated with long-term visual outcome in exudative age-related macular degeneration (eAMD) treated with intravitreal anti-vascular endothelial growth factor (VEGF), we tested the hypothesis that low dose proton beam treatment (PBT) with anti-VEGF reduced the volume of SRHM by reducing the fibrotic portion of choroidal neovascular membrane associated with eAMD.

Methods:

Interim analysis of baseline, 1 and 2 year OCT images of human eyes completing the 24 months follow-up as part of a prospective phase I/II randomized, prospective, sham-controlled study of PBT combined with antiVEGF therapy were analyzed for SRHM volume using the automated volume measure of subRPE lesion (Cirrus).

Eyes were randomized 1:1:1 to 24GyE PBT, 16GyE PBT or sham radiation and followed for antiVEGF treatment as needed based on new OCT fluid and/or macular hemorrhage after three monthly antiVEGF. There were a total of 15 eyes (15 patients). Fourteen of 15 eyes had subretinal hyper reflective material (SRHM) volumes ≥ 0.01 mm³ in the macula at baseline as measured by OCT. They include the following treatment randomization: 6 eyes treated with sham radiation; 8 eyes with PBT (3 with 16GyE, 5 with 24GyE).

Figure 1: Cirrus OCT of a patient comparing subretinal hyperreflective material at baseline and 2-year followup.



Results:

Subset analysis was conducted on 14 eyes that completed 24 months study follow-up with OCT SRHM volume of ≥ 0.01 mm³ at baseline due to limited accuracy of measuring very small volumes (n=5 24GyE, n=3 16GyE, n=6 sham).

Table 1: Characteristics of SRHM Volume at 3 Time Points:

Time Point	SRHM Mean Volume (mm ³)	SRHM Volume Range (mm ³)
Baseline	0.48 ± 0.62	0.01-2.05
12 month	0.38 ± 0.77	0-2.76
24 month	0.51 ± 1.04	0.01-3.84

No significant difference in mean volume was noted among groups at 12 and 24 months.

Table 2: The proportion with SRHM volume decreases by > 50% from baseline:

Time Point	24 GyE	16 GyE	Sham	P-value radiation vs sham
12 month	3/5	3/3	1/6	p = 0.03
24 month	2/5	2/3	0/5	p = 0.057

Conclusions:

Interim OCT analysis of eyes in this small prospective phase I/II sham controlled study of eAMD show a significantly higher proportion of eyes with greater than halving in volume of SRHM among eyes with eAMD treated with PBT and antiVEGF therapy as compared to antiVEGF monotherapy.

This supports the hypothesis that low dose radiation with intravitreal antiVEGF may reduce the size of SRHM in eAMD. A larger study may be warranted to further characterize this effect.

Acknowledgements:

-Supported in part by the Strategic Opportunities Support Award, Clinical and Translational Science Institute (UCSF).
-There are no conflicts of interest or financial disclosures related to this research.